Complications After Modified Dunn Osteotomy for the Treatment of Adolescent Slipped Capital Femoral Epiphysis

Vidyadhar V. Upasani, MD, Travis H. Matheney, MD, MLA, Samantha A. Spencer, MD, Young-Jo Kim, MD, PhD, Michael B. Millis, MD, and James R. Kasser, MD

Background: Modified Dunn osteotomy has gained popularity over the past decade in the treatment of moderate to severe adolescent slipped capital femoral epiphysis. The purpose of this study was to retrospectively evaluate a consecutive series of adolescent slipped capital femoral epiphysis patients treated with the modified Dunn procedure at a single institution. We analyze the indications for the procedure as well as the complications after surgical treatment.

Methods: Forty-three adolescent patients (18 boys and 25 girls) were treated with the modified Dunn procedure at our institution between September 2001 and August 2012. The average follow-up for this cohort was 2.6 years (range, 1 to 8 y). Complications were graded according to the modified Dindo-Clavien classification.

Results: Twenty-six patients (60%) had an unstable injury with an inability to ambulate with our without crutches. Seventeen patients (40%) had an acute injury with duration of symptoms <3 weeks. Thirty-seven patients (86%) had a severe slip based on a Southwick slip angle of >50 degrees. Twenty-two complications occurred in 16 patients (37%) in this cohort. Fifteen revision procedures were performed for femoral head avascular necrosis, fixation failure with deformity progression, or postoperative hip dislocation. Two patients developed end-stage degenerative joint disease and severe femoral head avascular necrosis and were referred for a total hip arthroplasty.

Conclusions: The complication rate in this series is higher than most previous reports. This may be in part because of the fact that as a tertiary referral center our patient population was more complex. However, we identified a clear inverse relationship between surgeon-volume and patient-outcomes. On the basis of our results we have modified our practice. A high-volume surgeon must be present during each modified Dunn procedure, and only patients that have sustained an acute severe (>50 degrees) epiphyseal displacement with mild chronic remodeling of the metaphysis that can be addressed within 24 hours of the slip may be treated with the modified Dunn technique.

Level of Evidence: Level IV—therapeutic study.

Key Words: slipped capital femoral epiphysis, modified Dunn osteotomy, complications

(*J Pediatr Orthop* 2014;34:661–667)

Capital realignment by Dunn osteotomy[1] through the surgical hip dislocation approach[2] has gained popularity over the past decade in the treatment of moderate to severe adolescent slipped capital femoral epiphysis (SCFE).[3] The primary advantage of this technique is that it allows near-anatomic restoration of proximal femoral anatomy; as residual metaphyseal deformity from even a mild slip has been shown to result in a cam-type femoroacetabular impingement resulting in premature damage to the acetabular labrum and articular cartilage.[4] The potential complications of this procedure, however, are numerous and can be devastating in the adolescent population. The most prevalent complications reported in the literature include implant failure requiring revision surgical fixation, nonunion of the proximal femoral physeal fracture or greater trochanteric osteotomy, and avascular necrosis (AVN) of the femoral head.[3,5–7]

The incidence of AVN is of particular interest. Historical studies have reported osteonecrosis rates ranging from 10% to 60% in surgically treated cases of SCFE depending on the age of the patient, severity of the slip, type of reduction, and location of osteotomy for deformity correction.[8–14] The modified Dunn procedure was developed to allow complete visualization of the retinacular vessels during reduction of the femoral head.[3] In theory, this technique would decrease the rate of AVN. The original review of this procedure performed at 2 institutions demonstrated no osteonecrosis or chondrolysis at a minimum of 1- to 3-year follow-up.[3] Subsequent studies, however, have reported between 5% and 30% incidence of AVN.[5–7]

The purpose of this study was to retrospectively evaluate a consecutive series of adolescent SCFE patients treated with the modified Dunn procedure at a single institution. We analyze the indications for the procedure as well as the complications following surgical treatment.

From the Department of Orthopedic Surgery, Boston Children's Hospital, Boston, MA.

No outside or institutional funding support was obtained for this study. The authors declare no conflicts of interest.

Reprints: Vidyadhar V. Upasani, MD, Department of Orthopedic Surgery, Boston Children's Hospital, 300 Longwood Avenue, Hunnewell Building—221, Boston, MA 02115. E-mail: vidyadhar.upasani@childrens.harvard.edu.

Copyright © 2014 by Lippincott Williams & Wilkins

METHODS

Forty-three adolescent patients with minimum 1-year postoperative follow-up were treated with the modified Dunn procedure at our institution between September 2001 and August 2012. Eighteen patients were boys with an average age at surgery of 12.6 years (range, 11 to 16 y) and 25 patients were girls with an average age at surgery of 11.4 years (range, 9 to 17 y). The average follow-up for this cohort was 2.6 years (range, 1 to 8 y). Three patients (7%) treated during this study period were lost to follow-up before their 1-year postoperative visit. These 3 patients have been excluded from the current analysis; however, to the best of our knowledge they have healed appropriately without any adverse complications. Of note, the first 10 consecutive patients in this cohort have been included in a previous publication.[3]

Surgical Technique

All patients were treated through a digastric trochanteric flip osteotomy and surgical hip dislocation through a z-shaped arthrotomy. The technical details of the procedure have been described previously.[2,3] Intraoperative monitoring of femoral epiphyseal perfusion was performed in each case. A 2-mm hole in the anterior femoral head[15] was used in 24 cases and an intracranial pressure (ICP) monitor[16] was used in 19 cases. To begin elevation of the retinacular flap, the femoral head was reduced into the acetabulum and the greater trochanter was excised using the so-called inside-out technique described by Ganz et al.[17] The retinacular vessels were carefully protected throughout the dissection and the periosteum was released distal to the greater trochanter. The residual physis was removed using a small curet and the dorsal metaphyseal callus was meticulously excised. Femoral head fixation varied between surgeons and over time. The greater trochanter was fixed with 2 or three 3.5-mm screws.

Complications were graded according to the adapted Dindo-Clavien classification.[18,19] Grade I complications require no treatment and have no clinical relevance with no deviation from routine follow-up. Grade II complications require deviation from the normal postoperative course and outpatient treatment either pharmacologic or close monitoring. Grade III complications require surgical or radiologic interventions or an unplanned hospital admission. Grade IV complications are life threatening, or have the potential for permanent disability. Death is a grade V complication.

TABLE 1. Preoperative Patient Classification

Loder Classification	Patient Cohort
Stable	17
Unstable	26
Fahey and O'Brien classification	
Acute	17
Acute on chronic	15
Chronic	11
Southwick slip angle	
Mild (<30 deg.)	0
Moderate (30 to 50 deg.)	6
Severe (>50 deg.)	37

Statistical Analysis

Fisher exact test was used to compare complication rates (grade III or higher) for binary and categorical variables. Each continuous variable was tested for normality and then tested with either a Mann-Whitney test or *t* test, as appropriate. Statistical significance was set at a *P*-value of 0.05.

RESULTS

Preoperative patient classification was determined based on hip stability,[20] duration of symptoms,[21] and the magnitude of the slip[22] (Table 1). Twenty-six patients (60%) had an unstable injury with an inability to ambulate with our without crutches. Seventeen patients (40%) had an acute injury with duration of symptoms <3 weeks. Thirty-seven patients (86%) had a severe slip based on a Southwick slip angle of >50 degrees.

Four surgeons performed all the procedures in his cohort. The volume of procedures varied between the surgeons. One surgeon performed the majority of procedures (70%). The remaining 3 surgeons performed 6, 5, and 2 procedures, respectively. A statistically significant association was found between surgeon and the incidence of complications ($P < 0.001$) (Table 2).

Twenty-two complications occurred in 16 patients (37%) in this cohort. Ten patients (23%) developed AVN of the femoral head. Four patients (9%) developed femoral neck nonunion requiring a revision surgical procedure. Two patients (5%) sustained a postoperative hip dislocation (Fig. 1).

There were 2 grade I complications including 1 patient with symptomatic heterotopic ossification over the greater trochanter and 1 patient with left hip wound drainage from a stitch abscess that required no additional treatment. Three patients had grade II complications due to femoral head AVN that required additional clinic visits and close monitoring with no further surgical intervention. Fifteen complications were grade III, requiring revision surgery. Fourteen revision procedures were for femoral head AVN, fixation failure, or postoperative dislocation. One patient had a scar revision procedure. Two patients had a grade IV complication after they developed end-stage degenerative joint disease and severe femoral head AVN (Fig. 2).

On reviewing the patients with AVN more closely, we found that 7 of 10 patients had undergone revision surgery. Four patients had a femoral head/neck osteochondroplasty to treat femoroacetabular impingement that resulted from lateral collapse of the femoral head. Three patients had more severe involvement and underwent an intertrochanteric osteotomy to reposition the viable portion of the femoral head into the weight-bearing region. Two patients had minimal deformity from anteromedial femoral head necrosis and have not required any further interventions in the short term. Both these patients are >2 years after operation. The final patient is 14 months after operation. He has significant femoral head collapse and will likely require an intertrochanteric

© 2014 Lippincott Williams & Wilkins

TABLE 2. Comparative Analysis by Complication (Grade III or Higher)

Variables	All Subjects N = 43	Complication(s) N = 13	No Complication(s) N = 30	*P*
Sex (males) [n (%)]	18 (42)	7 (54)	11 (37)	0.33
Age (mean ± SD) (y)	12.0 ± 1.7	12.2 ± 1.9	11.9 ± 1.6	0.64
Length of follow-up [median (IQR)] (y)	2.6 (1.1-7.7)	2.3 (1.2-2.9)	2.9 (1.1-7.7)	0.68
Fixation within 24 h [n (%)]	25 (58)	10 (77)	15 (50)	0.18
Previous in situ [n (%)]	7 (16)	1 (8)†	5 (17)	0.41
Chronicity [n (%)]				
Acute	17 (40)	6 (46)	11 (37)	0.70
Acute on chronic	15 (35)	5 (38)	10 (33)	
Chronic	11 (26)	2 (15)	9 (30)	
Severity (severe) [n (%)]	37 (86)	11 (85)	26 (87)	1.00
Southwick angle (mean ± SD)	68.8 ± 12.4	71.7 ± 15.1	67.6 ± 11.1	0.39
Stability (unstable) [n (%)]	26 (60)	9 (69)	17 (57)	0.51
Surgeon [n (%)]				
A	30 (70)	2 (15)	28 (93)	< 0.001*
B	5 (12)	5 (38)	0 (0)	
C	6 (14)	5 (38)	1 (3)	
D	2 (5)	1 (8)	1 (3)	

*Significant at the 5% level.
†Only 1 with grade III or higher complication.
IQR indicates interquartile range (25th percentile to 75th percentile).

osteotomy in the future. A statistically significant association was found between surgeon and the incidence of AVN ($P < 0.001$) (Table 3).

Seven patients in this cohort were initially treated with in situ fixation and revised with the modified Dunn procedure. Two patients had slip progression after in situ pinning. These patients were 5 and 9 months from their index procedure, respectively. The other 5 patients underwent in situ pinning either at an outside institution or at our facility. Revision surgery was performed between 12 days and 3 months after the index procedure. The indication for revision surgery was the severity of the proximal femoral deformity, which we thought would cause femoroacetabular impingement and early degeneration of the joint. In general these 7 patients fared similarly to the remainder of the cohort. The average follow-up for these 7 patients is 1.6 years (range, 1 to 3 y). Complications were observed in 2 of the 7 patients (29%). One patient developed AVN and did not require further surgical intervention during the follow-up period (grade II complication). The other sustained a postoperative dislocation and developed AVN requiring revision surgery (grade III complication).

Excluding these 7 patients, the time between initial presentation to our facility and surgical treatment averaged 43 hours (range, 1 to 408 h). A majority of patients (75%) were treated within 24 hours of presentation and all patients with acute SCFE symptoms were treated within 24 hours of presentation. Patients were in the hospital on average 4 days after surgery (range, 3 to 8 d).

DISCUSSION

The modified Dunn osteotomy is a powerful technique that corrects the deformity created by a SCFE and prevents the long-term sequela of femoroacetabular impingement created by the slip. Few manuscripts have been published that present the outcomes of this procedure in Europe and North America. In 2009, Ziebarth et al[3] reported short-term data on 40 consecutive patients from 2 institutions. Patients with established necrosis before the index procedure were excluded, as well as patients with renal insufficiency or other medical conditions. One patient who experienced deformity progression after previous in situ fixation was included in this analysis. No patients developed osteonecrosis or chondrolysis, and postoperative hip function was good with near normal range of motion for all patients. Four patients (10%) required revision surgery in this series. Three patients were revised for implant failure, however, they all subsequently healed with no loss of correction. In addition, 1 patient underwent osteochondroplasty 2 years after capital realignment for residual impingement.

In 2010, Slongo et al[7] reviewed 23 patients treated with the modified Dunn procedure with minimum 2-year follow-up. Complications occurred in 3 patients (13%). One patient had a chronic SCFE with full-thickness articular cartilage damage noted intraoperatively. At most recent follow-up, hip motion was significantly limited; however, the hip was reportedly pain free. A second patient developed severe femoral head osteonecrosis and eventually required a hip arthrodesis. This patient was found to have no intraoperative femoral head perfusion and at 2 weeks after operation, a bone scan confirmed the diagnosis of osteonecrosis. A third patient required a revision procedure for a prominent Kirschner wire.

In 2011, Huber et al[5] reviewed 30 hips in 28 patients with a mean follow-up of nearly 4 years. Three patients were classified as unstable according to the Loder classification.[20] Five patients (18%) experienced complications in the postoperative period. One patient developed femoral head AVN and required a revision procedure to back out the fixation as the femoral head began to collapse.

© 2014 Lippincott Williams & Wilkins

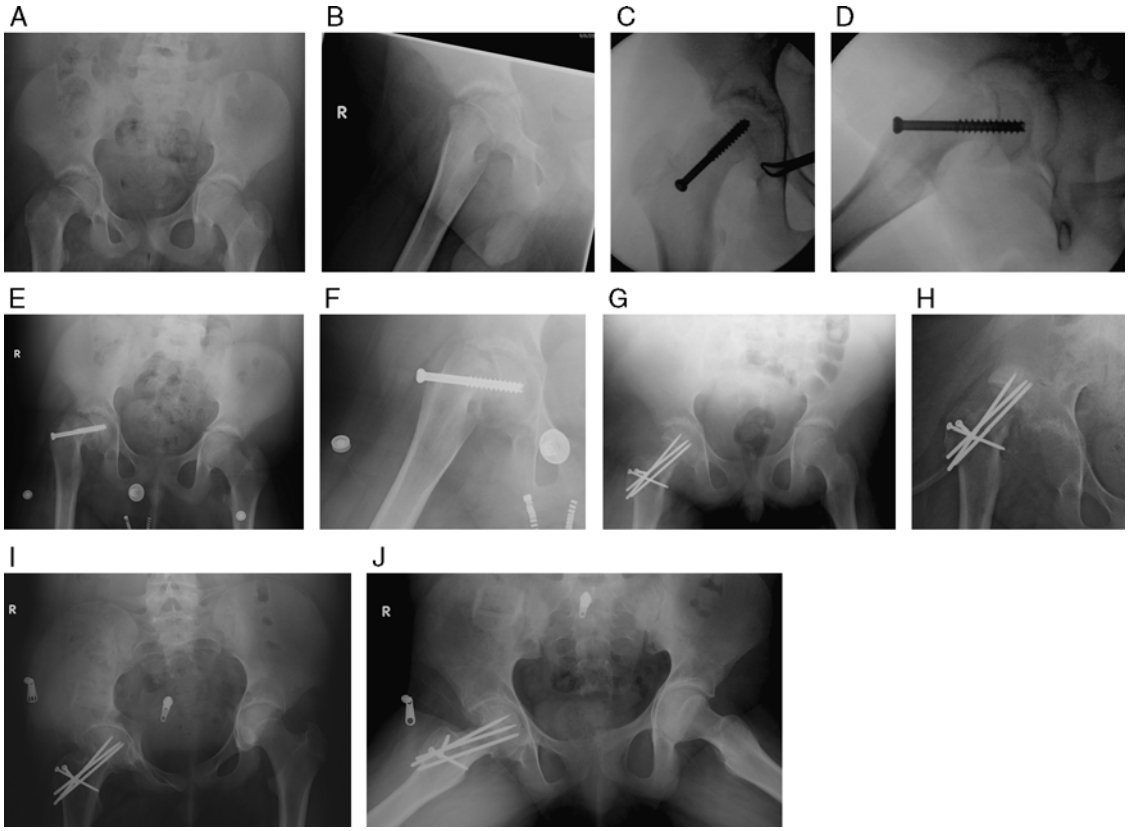

FIGURE 1. A 12-year-old male with several weeks of vague low back and right hip pain. Slipped and fell on day of presentation and was unable to bear weight. Anteroposterior (AP) pelvis (A) and right hip lateral (B) radiographs demonstrate a severe slipped capital femoral epiphysis. AP (C) and lateral (D) right hip fluoroscopic images after he underwent percutaneous in situ fixation within 24 hours of presentation. The patient was noncompliant in the postoperative period and ambulated without crutches at 3 weeks after operation. He presented to clinic with worsening pain and a limp and on AP pelvis (E) and right hip lateral (F) radiographs he was found to have progression of the slip. Five months after the index procedure, he underwent the modified Dunn procedure with the postoperative AP pelvis radiograph shown (G). On postoperative day 10 from this procedure he was found to have a high hip dislocation on an AP right hip radiograph (H). After failed closed reduction attempts he underwent open reduction. He was managed in a spica cast for 6 weeks followed by a hip abduction brace for an additional 6 weeks. AP (I) and frog (J) pelvis radiographs at 18 months postoperation demonstrate a healed slip with evidence of healing femoral head osteonecrosis. He ambulates without pain or limp. On examination, he has a 5-degree hip flexion contracture. He is able to flex his hip to 100 degrees and has 20 degrees of internal rotation and 40 degrees of external rotation.

This patient was noted to have no femoral head perfusion intraoperatively before and after epiphyseal repositioning. Four other patients required revision surgery for fixation failure. Despite these complications, they reported excellent outcomes in 28 hips with near-anatomic epiphyseal reduction in all the cases.

In 2013, Madan et al[6] reported on 28 patients with a mean follow-up of 38 months. Seventeen patients had unstable slips and 5 had previous in situ pinning at other institutions. Five patients (18%) experienced complications in the postoperative period. Four patients (14%) developed AVN. Two had been fixed in situ and had no femoral head perfusion on a preoperative bone scan. The other 2 had no blood flow on intraoperative drilling of the femoral head. Three of these patients underwent arthrodiastasis and 1 required a pelvic support osteotomy. One additional patient in this series developed severe chondrolysis and required a pelvic support osteotomy.

Also in 2013, Sankar et al[23] reported on 27 patients from 5 different pediatric centers with a mean follow-up of 22 months. All patients in this series had unstable slips. Seven patients (26%) developed osteonecrosis, 4 patients (15%) had broken epiphyseal implants, and 8 patients (29%) required revision surgery. Overall the complication rate was 41%.

The complication rate in our case series (37%) is significantly higher than previous publications and comparable with the recent Sankar et al's[23] manuscript. This may be in part, due to the fact that as a tertiary referral center our patient population was more complex. One patient developed a slip 5 months after open reduction internal fixation of an ipsilateral femoral neck fracture. Three patients had endocrine abnormalities that required medical management and 1 patient had severe schizophrenia that limited compliance with postoperative restrictions. In addition, this case series included 26

 © 2014 Lippincott Williams & Wilkins

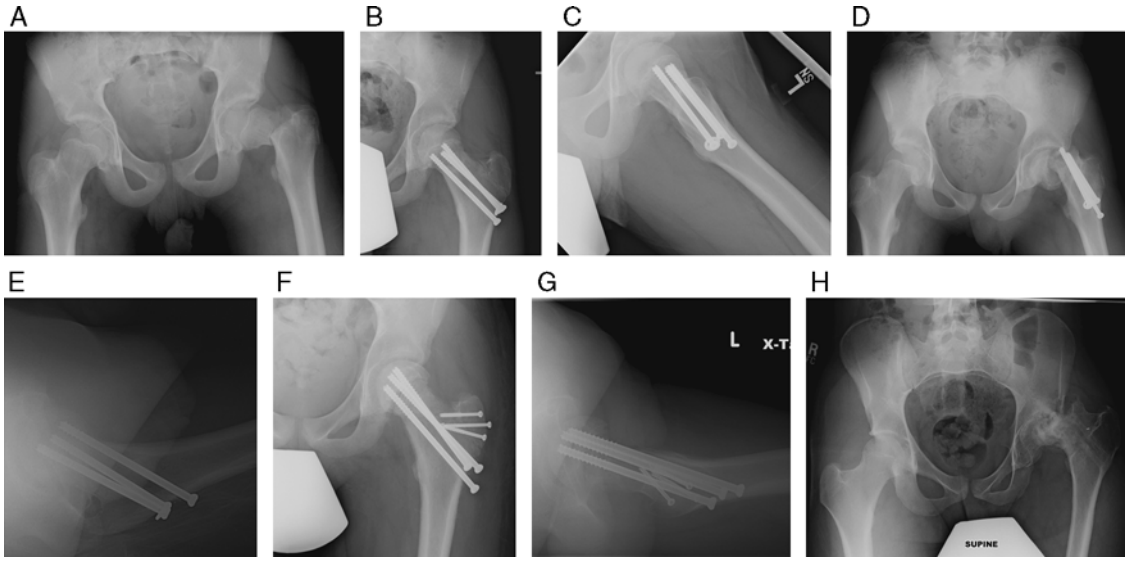

FIGURE 2. Anteroposterior (AP) pelvis radiographs (A) of a 13-year-old male who sustained a left femoral neck fracture after falling off his bicycle. Postoperative AP (B) and lateral (C) left hip radiographs after he underwent open reduction internal fixation. AP pelvis (D) and lateral left hip (E) radiographs at 5 months postoperative when he presents with acute onset of left hip pain after a slip and fall on ice. He was treated with a modified Dunn osteotomy. Postoperative AP (F) and lateral (G) left hip radiographs are shown. The patient subsequently developed femoral head osteonecrosis. The screws were revised, however, eventually had to be removed. AP pelvis radiograph (H) at most recent follow-up, 4 years after operation, the patient has a 9 cm functional leg length discrepancy. He has limited hip flexion to 75 degrees, 10 degrees of hip abduction, 5 degrees of internal rotation, and no external rotation.

unstable hips (60%), 32 patients (74%) with acute or acute on chronic symptoms, 37 patients (86%) with > 50 degrees of slip using the Southwick method, and 7 patients (16%) that had failed previous in situ pinning. None of these variables, however, were significantly associated with the incidence of complications in this series (Table 2).

Two patients (5%) sustained a postoperative hip dislocation. Our theory as to the etiology of this instability is that in these chronic SCFE patients the anterior capsule is often attenuated and the anterior rim/labrum is damaged from the displaced neck. The proximal femur is also severely retroverted because of the SCFE deformity causing the hip to develop an external rotation soft-tissue contracture. When the bony deformity is acutely corrected, anteverting the proximal femur, the soft-tissue contractures and the anterior damaged structures predispose the hip to be unstable

TABLE 3. Comparative Analysis for Avascular Necrosis (AVN)

Variables	AVN N = 10	No AVN N = 33	*P*
Sex (males) [n (%)]	6 (60)	11 (34)	0.27
Age (mean ± SD) (y)	12.4 ± 1.9	11.8 ± 1.6	0.37
Length of follow-up [median (IQR)] (y)	2.8 (1.1-2.4)	3.1 (1.5-7.7)	0.65
Fixation within 24 h [n (%)]	7 (70)	18 (56)	0.49
Previous in situ [n (%)]	2 (20)	5 (16)	1.00
Chronicity [n (%)]			
Acute	3 (30)	14 (44)	0.21
Acute on chronic	6 (60)	9 (28)	
Chronic	1 (10)	10 (30)	
Severity (severe) [n (%)]	8 (80)	28 (88)	0.62
Southwick angle (mean ± SD)	69.7 ± 16.4	68.1 ± 11.0	0.77
Stability (unstable) [n (%)]	7 (70)	19 (59)	0.72
Surgeon [n (%)]			
A	2 (20)	28 (88)	< 0.001*
B	2 (20)	3 (9)	
C	5 (50)	1 (3)	
D	1 (10)	1 (3)	

*Significant at the 5% level.
AVN indicates avascular necrosis; IQR, interquartile range (25th percentile to 75th percentile).

© 2014 Lippincott Williams & Wilkins

anteriorly. In addition, the anterior joint capsule is extensively opened during the procedure and is closed loosely to prevent vascular insult to the femoral head. If the leg position is not monitored closely in the postoperative period, these patients are at risk for instability.

Ten patients (23%) developed AVN of the femoral head. Intraoperative assessment of femoral head perfusion, however, did not correlate with postoperative outcomes in this case series. Five patients had no bleeding from the 2-mm hole created intraoperatively in the anterior femoral epiphysis. However, only one of these 5 patients went on to develop osteonecrosis. In contrast, 9 patients developed AVN who either had brisk bleeding from the femoral head or triphasic waveforms with ICP monitoring of femoral head perfusion. Nevertheless, we feel that intraoperative monitoring of femoral head perfusion is critical in obtaining a successful outcome. Since we started using ICP monitoring, we have identified the need to modify our epiphyseal reduction to optimize femoral head perfusion. For example, overreduction of the femoral head into a flexed or valgus position can stretch the retinacular vessels and disrupt perfusion. This needs to be immediately addressed by either backing off on the reduction or by slightly shortening the femoral neck to relax the vessels.

Surgeon-volume and experience with this procedure demonstrated an inverse relationship with outcomes in this patient cohort and was the one variable significantly associated with grade III or IV complications ($P < 0.001$). We have been performing surgical hip dislocations at our institution since 2001 and have performed 683 of these procedures between 2001 and 2012. The modified Dunn procedure is performed much less frequently. We treat on average 50 SCFE patients each year and over the past 11 years we have performed < 50 modified Dunn procedures in total. Of those, 1 surgeon performed 70% of the surgeries (30 cases) and experienced 6 complications in 5 patients (17%). Two patients developed femoral head osteonecrosis, 2 patients developed nonunion of the SCFE, and 1 patient developed asymptomatic heterotopic ossification. The remaining 3 surgeons performed 6, 5, and 2 cases, respectively, and had complication rates between 50% and 100%. This relationship between surgeon-volume and patient-outcomes has been studied in a variety of surgical subspecialties[24–29] and may play an important role in the future certification of surgeons to perform technically demanding procedures.

In 1979, Luft et al[30] were the first to promote the concept that the number of procedures a surgeon performs could predict patient outcomes. Since then health outcomes researchers have used large databases to elucidate this relationship and have recommended selective referral of complicated patients requiring technically challenging procedures to high-volume hospitals.[31] Shervin et al[32] recently performed a systematic review on orthopaedic procedure volume and patient-outcomes. They found a significant association between higher hospital volume and surgeon-volume on the rates of morbidity and mortality after orthopaedic procedures. Interestingly, surgeon-volume had a greater effect on patients than hospital volume for primary and revision joint arthroplasties.[32] This may also be true for the modified Dunn procedure.

Within our institution, despite being a high-volume center, we identified differing complication rates between surgeons and decided to perform this retrospective review as a quality improvement project. On the basis of our results, we have modified our practice patterns. Primarily, the high-volume surgeon must be present during each modified Dunn procedure, especially because on average < 5 of these procedures are performed annually. Secondly, we have modified our surgical indications for this procedure to only include patients who have sustained an acute severe (> 50 degrees) epiphyseal displacement with minimal chronic remodeling of the metaphysis that can be addressed within 24 hours of the slip. Patients who do not meet these inclusion criteria are treated with in situ pinning versus open anterior reduction and fixation based on the chronicity and severity of the slip, and are counseled that further surgery may be required to treat the residual proximal femoral deformity. Time will tell if this strategy is effective to reduce our complication rates.

REFERENCES

1. Dunn DM. The treatment of adolescent slipping of the upper femoral epiphysis. *J Bone Joint Surg Br*. 1964;46:621–629.
2. Ganz R, Gill TJ, Gautier E, et al. Surgical dislocation of the adult hip a technique with full access to the femoral head and acetabulum without the risk of avascular necrosis. *J Bone Joint Surg Br*. 2001;83:1119–1124.
3. Ziebarth K, Zilkens C, Spencer S, et al. Capital realignment for moderate and severe SCFE using a modified Dunn procedure. *Clin Orthop Relat Res*. 2009;467:704–716.
4. Leunig M, Casillas MM, Hamlet M, et al. Slipped capital femoral epiphysis: early mechanical damage to the acetabular cartilage by a prominent femoral metaphysis. *Acta Orthop Scand*. 2000;71:370–375.
5. Huber H, Dora C, Ramseier LE, et al. Adolescent slipped capital femoral epiphysis treated by a modified Dunn osteotomy with surgical hip dislocation. *J Bone Joint Surg Br*. 2011;93:833–838.
6. Madan SS, Cooper AP, Davies AG, et al. The treatment of severe slipped capital femoral epiphysis via the Ganz surgical dislocation and anatomical reduction: a prospective study. *Bone Joint J*. 2013;95-B:424–429.
7. Slongo T, Kakaty D, Krause F, et al. Treatment of slipped capital femoral epiphysis with a modified Dunn procedure. *J Bone Joint Surg Am*. 2010;92:2898–2908.
8. Boyer DW, Mickelson MR, Ponseti IV. Slipped capital femoral epiphysis. Long-term follow-up study of one hundred and twenty-one patients. *J Bone Joint Surg Am*. 1981;63:85–95.
9. Broughton NS, Todd RC, Dunn DM, et al. Open reduction of the severely slipped upper femoral epiphysis. *J Bone Joint Surg Br*. 1988;70:435–439.
10. Clarke HJ, Wilkinson JA. Surgical treatment for severe slipping of the upper femoral epiphysis. *J Bone Joint Surg Br*. 1990;72:854–858.
11. Kennedy JG, Hresko MT, Kasser JR, et al. Osteonecrosis of the femoral head associated with slipped capital femoral epiphysis. *J Pediatr Orthop*. 2001;21:189–193.
12. Loder RT. Unstable slipped capital femoral epiphysis. *J Pediatr Orthop*. 2001;21:694–699.
13. Nishiyama K, Sakamaki T, Ishii Y. Follow-up study of slipped capital femoral epiphysis. *J Pediatr Orthop*. 1989;9:653–659.
14. Tokmakova KP, Stanton RP, Mason DE. Factors influencing the development of osteonecrosis in patients treated for slipped capital femoral epiphysis. *J Bone Joint Surg Am*. 2003;85-A:798–801.
15. Gill TJ, Sledge JB, Ekkernkamp A, et al. Intraoperative assessment of femoral head vascularity after femoral neck fracture. *J Orthop Trauma*. 1998;12:474–478.

© 2014 Lippincott Williams & Wilkins

16. Notzli HP, Wyss TF, Stoecklin CH, et al. The contour of the femoral head-neck junction as a predictor for the risk of anterior impingement. *J Bone Joint Surg Br*. 2002;84:556–560.
17. Ganz R, Huff TW, Leunig M. Extended retinacular soft-tissue flap for intra-articular hip surgery: surgical technique, indications, and results of application. *Instr Course Lect*. 2009;58:241–255.
18. Clavien PA, Strasberg SM. Severity grading of surgical complications. *Ann Surg*. 2009;250:197–198.
19. Dindo D, Demartines N, Clavien PA. Classification of surgical complications: a new proposal with evaluation in a cohort of 6336 patients and results of a survey. *Ann Surg*. 2004;240:205–213.
20. Loder RT, Richards BS, Shapiro PS, et al. Acute slipped capital femoral epiphysis: the importance of physeal stability. *J Bone Joint Surg Am*. 1993;75:1134–1140.
21. Fahey JJ, O'Brien ET. Acute slipped capital femoral epiphysis: review of the literature and report of ten cases. *J Bone Joint Surg Am*. 1965;47:1105–1127.
22. Jones JR, Paterson DC, Hillier TM, et al. Remodelling after pinning for slipped capital femoral epiphysis. *J Bone Joint Surg Br*. 1990;72:568–573.
23. Sankar WN, Vanderhave KL, Matheney T, et al. The modified dunn procedure for unstable slipped capital femoral epiphysis: a multicenter perspective. *J Bone Joint Surg Am*. 2013;95:585–591.
24. Kizer KW. The volume-outcome conundrum. *N Engl J Med*. 2003;349:2159–2161.
25. Jollis JG, Romano PS. Volume-outcome relationship in acute myocardial infarction: the balloon and the needle. *JAMA*. 2000;284:3169–3171.
26. Lee JA, Morrison SL, Morris JN. Fatality from three common surgical conditions in teaching and non-teaching hospitals. *Lancet*. 1957;273:785–790.
27. Begg CB, Cramer LD, Hoskins WJ, et al. Impact of hospital volume on operative mortality for major cancer surgery. *JAMA*. 1998; 280:1747–1751.
28. Hannan EL, Radzyner M, Rubin D, et al. The influence of hospital and surgeon volume on in-hospital mortality for colectomy, gastrectomy, and lung lobectomy in patients with cancer. *Surgery*. 2002;131:6–15.
29. Finlayson EV, Goodney PP, Birkmeyer JD. Hospital volume and operative mortality in cancer surgery: a national study. *Arch Surg*. 2003;138:721–725; discussion 726.
30. Luft HS, Bunker JP, Enthoven AC. Should operations be regionalized? The empirical relation between surgical volume and mortality. *N Engl J Med*. 1979;301:1364–1369.
31. Dudley RA, Johansen KL, Brand R, et al. Selective referral to high-volume hospitals: estimating potentially avoidable deaths. *JAMA*. 2000;283:1159–1166.
32. Shervin N, Rubash HE, Katz JN. Orthopaedic procedure volume and patient outcomes: a systematic literature review. *Clin Orthop Relat Res*. 2007;457:35–41.

© 2014 Lippincott Williams & Wilkins