

The Safe Zone for External Fixator Pins in the Femur

Michael J. Beltran, MD,* Cory A. Collinge, MD,† Jeanne C. Patzkowski, MD,* Brendan D. Masini, MD,* Robert E. Blease, MD,‡ Joseph R. Hsu, MD,§ and the Skeletal Trauma Research Consortium (STReC)

Objective: To define the anatomic “safe zone” for placement of external fixator half pins into the anterior and lateral femur.

Methods: In 20 fresh-frozen hemipelvis specimens, the femoral nerve and all branches crossing the femur were dissected out to their final muscular locations. The location where the nerves crossed the anterior femur was measured from the anterior superior iliac spine and inferior margin of the lesser trochanter. The knee joint was then opened, and the distance from the superior reflection of the suprapatellar pouch to the last branch of the femoral nerve crossing the anterior femur was measured, defining the safe zone for anterior pin placement.

Results: The last branch of the femoral nerve crossed at an average distance from the anterior superior iliac spine of 174 ± 43 mm (range, 95–248 mm) and from the lesser trochanter at a distance of 58 ± 36 mm (range, 0–136 mm). The average distance from the proximal pole of the patella to the superior reflection of the suprapatellar pouch was 46.3 ± 13.1 mm (range, 20–74 mm). Using the linear distance between the last crossing femoral nerve branch and the superior reflection of the pouch, the average safe zone measured 199 ± 39.8 mm (range, 124–268 mm). The safe zone correlated with thigh length ($r = 0.48$, $P = 0.03$). All nerve branches terminated at their muscular origins without crossing lateral to a line from the anterior greater trochanter to the anterior aspect of the lateral femoral condyle.

Conclusions: The safe zone for anterior external fixator half pin placement into the femur is on average 20 cm in length and can be as narrow as 12 cm. Anterior pins should begin 7.5 cm above the superior pole of the patella to avoid inadvertent knee joint penetration. Because the entire lateral femur is safely available for half pin placement, including distally, we recommend the use of

alternative frame constructs with either anterolateral or lateral pins given the limitations and risks of anterior pin placement.

Key Words: safe zone, external fixation, femur, knee-spanning

(*J Orthop Trauma* 2012;26:643–647)

INTRODUCTION

Placement of external fixator half pins into the femoral shaft is recommended during a number of situations, including damage control situations and spanning of the knee joint after high-energy periarticular fracture or dislocation.^{1–6} Optimal placement of pins requires a thorough knowledge of cross-sectional limb anatomy to avoid inadvertent neurovascular injury and intra-articular pin penetration.^{7,8} Pins placed into the shaft of the femur can be in a lateral, anterolateral, or anterior position. Lateral pin placement is advantageous because violation of the extensor mechanism is avoided while limiting risk to neurovascular structures and inadvertent knee joint penetration.⁵ Use of anterior pins is well described in the literature, particularly in knee spanning situations, but is associated with substantially more risk to neurovascular structures than further lateral pins, may lead to inadvertent knee joint penetration through the suprapatellar pouch, and may lead to heterotopic ossification (HO) within the quadriceps muscle with resultant limited range of motion and a poorer functional outcome.^{3,4,6,9,10} Despite these limitations, a recent survey of the Orthopaedic Trauma Association membership identified that a majority of practicing orthopaedic trauma surgeons still prefer to use anterior femoral pins when placing a knee spanning external fixator.¹¹ Pin placement in the femur is currently the subject of an ongoing prospective randomized clinical trial.¹²

The purpose of the present study was to define the safe zone for placement of external fixator pins into the femur. We hypothesized that a relatively narrow corridor would be available for pin placement anteriorly between the crossing femoral nerve branches proximally and the reflection of the suprapatellar pouch distally, making safe placement of multiple anterior pins challenging in most clinical situations.

MATERIALS AND METHODS

Twenty fresh-frozen cadaveric hemipelvis specimens were used for this study (LifeLegacy, Phoenix, AZ). Full-thickness skin and subcutaneous flaps were raised laterally and medially, the sartorius was cut at its origin and lifted distally, and the femoral nerve and its branches dissected out

Accepted for publication January 12, 2012.

From the *Department of Orthopaedics and Rehabilitation, San Antonio Military Medical Center, San Antonio, TX; †Orthopaedic Specialty Associates, Fort Worth, TX; ‡United States Army Trauma Training Center/Ryder Trauma Center, Miami, FL; and §Department of Orthopaedics, US Army Institute of Surgical Research, San Antonio, TX.

Supported by funding from the United States Army Institute of Surgical Research. None of the authors have any financial disclosures directly related to this research project.

The opinions or assertions contained herein are the private views of the authors and are not to be construed as official or as reflecting the views of the Department of the Army or the Department of Defense.

Investigation was performed at the United States Army Institute of Surgical Research, San Antonio, TX 78234.

The authors declare no conflict of interest.

Reprints: Michael J. Beltran, MD, Department of Orthopaedics and Rehabilitation, San Antonio Military Medical Center, San Antonio, TX 78234 (e-mail: michael.beltran@amedd.army.mil).

Copyright © 2012 by Lippincott Williams & Wilkins

in their entirety from proximal to distal until the last branch crossing the anterior femur was exposed. The femoral artery and vein were not dissected out in this study. A lateral knee arthrotomy was performed, and a 5-mm Schanz pin was introduced into the knee joint parallel to the lateral joint line to identify the superior reflection of the suprapatellar pouch. Another Schanz pin was placed into the knee joint at and parallel to the lateral joint line, indicating the distal extent of the femur. A final Schanz pin was then inserted along the inferior margin of the lesser trochanter (LT), perpendicular to the femoral shaft. The final step involved palpation of the superior border of the patella, which was marked.

Using a metric ruler, standard measurements were taken as follows. The distance from the center of the anterior superior iliac spine (ASIS) to the lateral joint line was measured to establish overall thigh length. The distance from the lateral joint line to the superior reflection of the suprapatellar pouch and the distance from the superior aspect of the patella to the reflection of the suprapatellar pouch were also measured. When measuring to the lateral joint line or superior reflection of the suprapatellar pouch, the center of the Schanz pin was used for measurements. When measuring to the LT, the superior edge of the pin was used because this aspect of the pin was directly adjacent to the inferior margin of the LT. Values relative to the LT were reported as negative if they crossed above the reference pin and as zero if they crossed directly adjacent to the reference pin (Fig. 1).

The distance to each branch of the femoral nerve that was found to cross the anterior femur was then measured from the center of the ASIS and the inferior margin of the LT; nerves were labeled as crossing proximal, at the level of, or distal to the inferior margin of the LT. Nerve branches were dissected out to their final muscular origins in all limbs, and the muscles innervated were documented. We defined the lateral femur as anything lateral to a line from the anterior aspect of the greater trochanter to the anterior aspect of the lateral femoral condyle.

Demographic data for all cadavers were documented to include race, gender, height, and weight. Collected data were analyzed for statistical significance using Student *t* test, χ^2 test, or Fisher exact test, as appropriate. All reported *P* values are 2 tailed, with a $P \leq 0.05$ determining statistical significance. Statistical analysis was performed with SAS 9.1 (Cary, NC).

RESULTS

Description of Nerve Anatomy

The first branch crossed the femur at an average distance from the ASIS of 107 ± 22 mm (range, 60–148 mm). The first branch was, on average, 19.9 ± 17.6 mm (range, –60 to +17 mm) from the LT, with 14 branches crossing proximal, 3 crossing distal, and 3 crossing directly over the LT. The last branch crossed the midline of the anterior femur at an average distance from the ASIS of 174 ± 43 mm (range, 95–248 mm) and from the LT at a distance of 58 ± 36 mm (range, 0–136 mm). The last branch crossed, on average, 245 ± 44 mm (range, 164–320 mm) from the proximal pole of the patella. The average number of femoral nerve branches crossing the

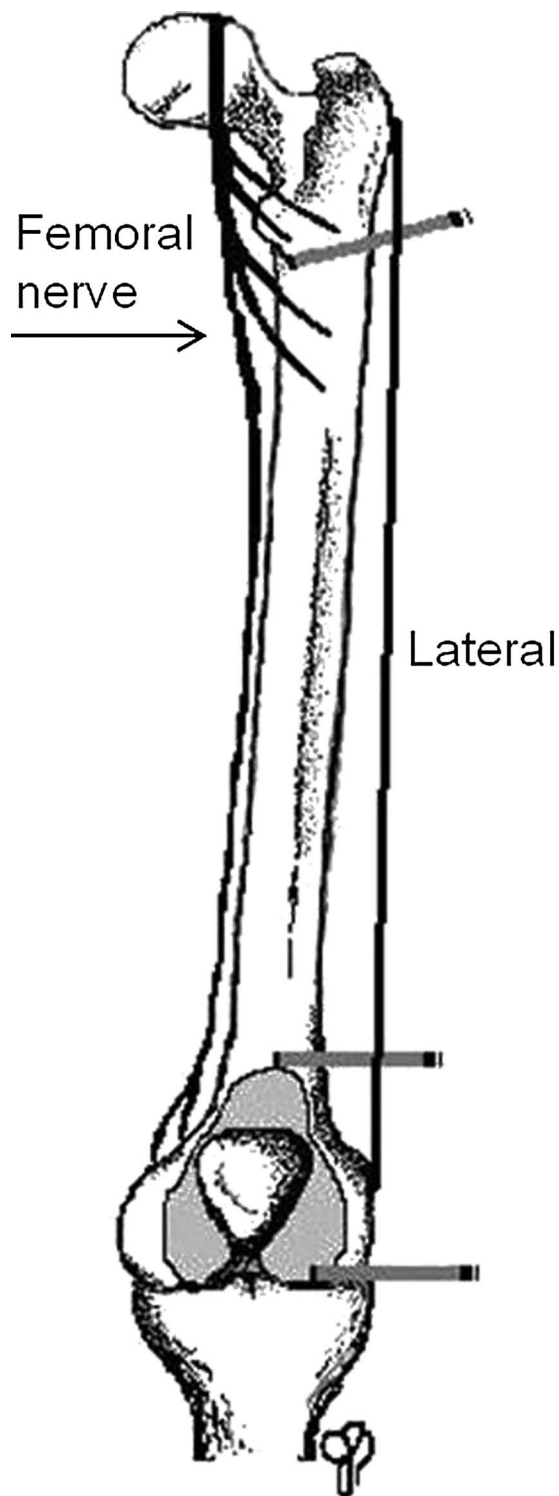


FIGURE 1. Drawing depicting reference pin placement. The first pin was placed at the inferior LT, perpendicular to the shaft of the femur. The final 2 pins were placed parallel to the knee joint distally and to mark the superior extent of the suprapatellar pouch.

anterior femur was 4.35 (range, 2–6). The rectus femoris was typically innervated by 1 of the first 2 branches, whereas the vastus intermedius and lateralis were typically innervated by more distal branches. A full description of muscle innervation by the various nerve branches is listed in Table 1. In all specimens, branches terminated into muscle bellies as they traversed laterally, and none were found to extend beyond a line from the anterior greater trochanter to the anterior lateral femoral condyle.

In all 20 specimens, there were a total of 2 anomalous nerves. In the first specimen, the first branch contacted the anterior femur, but instead of immediately crossing it, and coursed directly anterior over the proximal femur for a distance of 4.8 cm proximal to the level of the LT (Figure 2). In the second specimen, a second crossing branch gave rise to a sizeable accessory branch, which coursed distally adjacent to the main femoral nerve for a distance of 9 cm before coursing laterally across the femur.

Description of Suprapatellar Anatomy and the Safe Zone

The average distance from the proximal pole of the patella to the superior reflection of the suprapatellar pouch was 46.3 ± 13.1 mm (range, 20–74 mm). The longest synovial reflection extended 7.4 cm above the patella. The average distance of the superior reflection from the lateral joint line measured 94.9 ± 16.5 mm (range, 57–115 mm). Using the linear distance between the last crossing femoral nerve branch and the superior reflection of the pouch, the average safe zone measured 199 ± 39.8 mm. The smallest individual safe zone was 124 mm, and the largest was 268 mm. Safe zone length ($r = 0.48, P = 0.03$) and distance from the lateral joint line to the superior reflection of the pouch ($r = 0.73, P < 0.005$) both correlated with thigh length (average 464.8 ± 50.2 mm; range, 383–550 mm; Fig. 3).

DISCUSSION

Placement of external fixator pins into the femur has traditionally been performed with pins positioned anterior, lateral, or anterolateral. Although some surgeons advocate the

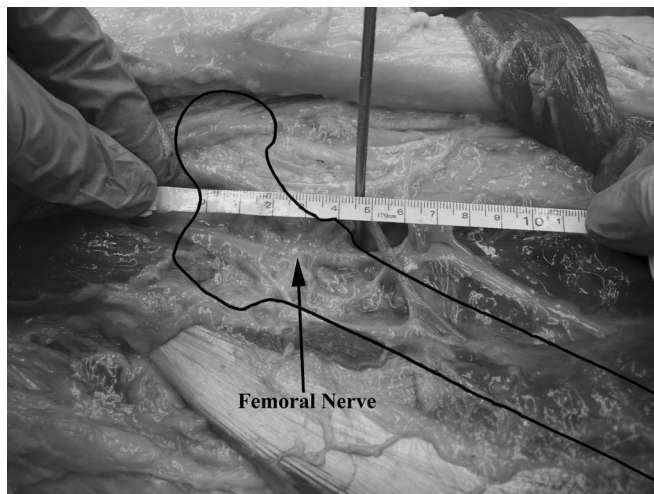


FIGURE 2. Image depicting an anomalous nerve branch, coursing along the anterior femur for a distance of 4.8 cm above the LT.

use of anterolateral or lateral pins to avoid the extensor mechanism and knee joint,⁵ many recent reports have continued to describe the use of anterior external fixator pins in the femur for knee spanning applications, and a recent survey indicated that nearly two-thirds of orthopaedic trauma surgeons prefer anterior pins when spanning the knee.^{3,6,9,11} Survey respondents also heavily favored the use of proximal pins for distal femur fracture applications, a location which has previously been demonstrated to place neurovascular structures at risk with interlocking of retrograde femoral nails.¹⁰ Anterior femoral pins have also been recommended in far forward combat situations because of ease in patient loading and transport.¹³ Unlike anterolateral or lateral pins, anterior pins have been associated with HO within the quadriceps muscle and place femoral nerve and arterial branches at risk more proximally; distally inadvertent knee joint penetration is possible through the reflection of the suprapatellar pouch.^{3,10} Egol et al³ found HO within the quadriceps as an unexpected complication of anterior pins when spanning the knee joint for staged reconstruction of high-energy proximal tibia fractures. Strengthening the argument against anterior femoral pins, a recent biomechanical study indicated that anterolateral femoral pins connected to anteromedial tibial pins were a more stable construct than anterior femoral pins for knee spanning situations, presumably due to the biplanar nature of the construct.^{14–16}

Riina et al¹⁰ reported on the neurovascular risks associated with anterior to posterior directed interlocking screws in retrograde femoral nailing. In 60 cadaveric dissections, they identified an average of 7 femoral nerve branches, with the first branch crossing the anterior femur approximately 4 cm distal to the piriformis fossa. Eighteen of 60 specimens had no branches proximal to the LT. Based on their results, they concluded that interlocking screws should be placed above the level of the LT to limit potential injury to crossing nerve branches. No mention is made of the absolute number of crossing nerve branches, however, or of the distance to the

TABLE 1. Innervation of Quadriceps Muscle Based on Branching Pattern

Branch (No. Specimens)	Rectus Femoris (no.)	Vastus Intermedius (no.)	Vastus Lateralis (no.)
1 (most proximal), (20 specimens)	20	3	2
2 (20 specimens)	15	8	4
3 (19 specimens)	3	8	14
4 (15 specimens)	1	9	14
5 (9 specimens)	1	6	8
6 (3 specimens)	0	3	3

In all 20 cadaveric specimens, there were at least 2 nerve branches. In 1 specimen (5%), branch 2 was the last branch crossing the femur, but the majority of specimens (60%) had 5 or 6 crossing branches. The rectus femoris was predominantly innervated by the first 2 branches, whereas the vastus intermedius and lateralis received their dominant innervations from more distal branches.

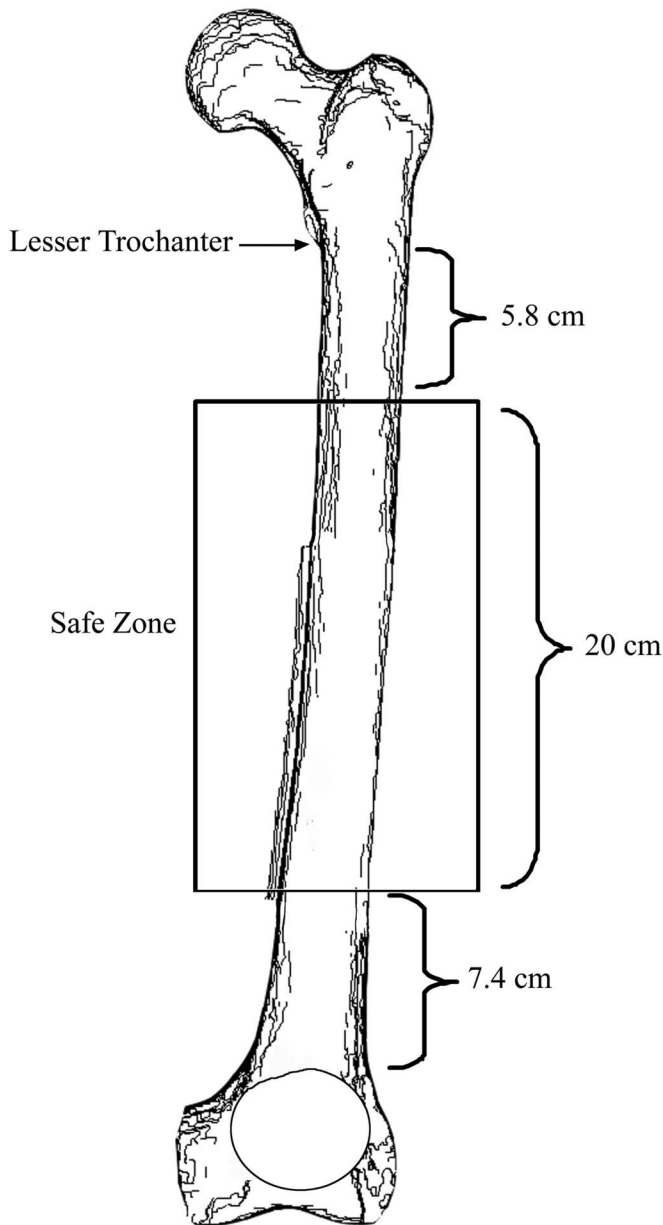


FIGURE 3. Drawing demonstrating the average anterior safe zone in relation to key palpable and radiographic structures: the LT proximally and the suprapatellar pouch distally.

most distal crossing branch. The results of our study are comparable to those of Riina et al¹⁰ when evaluating the proximal anatomy of the femoral nerve. In our series of 20 cadaveric specimens, 55% had at least 1 branch crossing proximal to the LT, with a maximum of 4 branches crossing proximal. A major difference in findings between our study and that of Riina et al,¹⁰ however, is in describing the absolute number of branches crossing the femur. Riina et al described an average number of femoral nerve branches of 7 ± 2 , with a wide range of 4–12. In our series, no cadaveric limb had more than 6, with an average of 4.35. We only counted and dissected in detail branches that actually crossed over the

anterior femur, and this may explain the difference. Riina et al did not mention whether they only included crossing branches or whether they also included branches coursing to the vastus medialis. Medial branches are irrelevant in a discussion of anterior fixator pins, however, as injury to them (and to the femoral artery proper) is minimized or eliminated by avoiding errant medial pin placement.

In all 20 cadaveric specimens, nerve branches terminated into their final muscular destinations without crossing over the lateral femur. This point is important when considering pin placement because it indicates that the entire lateral femur is safe for placement of pins. Anterolateral pins should also be considered safe because penetration through the quadriceps lateral to the shaft of the femur does not place nerve branches at risk before their termination into muscle bellies. The branching pattern of the femoral nerve structures also warrants attention when considering pin placement. In the 20 cadaveric specimens studied, the rectus femoris received the majority of its innervations from proximal branches (87.5% of the time) crossing near the LT, with the most proximal branch innervating the rectus femoris in every specimen (Table 1). In contrast, the vastus intermedius and lateralis had a broad innervation pattern, with a majority of their innervation coming from more distal branches. Anterior pins placed proximal near the LT that injure nerve branches can be expected to lead to possible weakness in the rectus femoris, whereas pins more distal, at the margin of the safe zone, would be expected to lead to possible weakness in the vastus intermedius and/or lateralis.

The results of our study indicate that palpation of the proximal pole of the patella may allow for safe placement of anterior fixator pins in the distal femur as long as knowledge of suprapatellar anatomy is considered. Because the joint reflection can be as much as 7.4 cm from the palpable superior border of the patella, anterior pins should be placed at least 7.5 cm further than this to avoid inadvertent intra-articular penetration and the potential for septic arthritis. This is particularly important in patients of tall stature because the superior reflection of the joint relative to the patella correlates with femoral length.

Based on the distance between the last crossing femoral nerve branch and the superior reflection of the knee joint, the average safe zone corridor for anterior external fixator pin placement is approximately 20 cm, with the absolute narrowest zone identified as 12 cm in this study (Fig. 3). This represents a relatively small corridor for anterior external fixator pin placement, and if chosen, anterior pins should be placed with caution. Because surgeons have recently indicated a preference for free hand placement of pins and clamps as opposed to the use of multi-pin clamps, situations where wide anterior pin spread are desired cannot be considered safe.¹¹ Our results suggest that other pin locations should be considered in most clinical situations. Because no nerve branches were in contact with the lateral femur and all terminated into muscle bellies, the entire lateral femur should be considered safe when placing pins. Furthermore, the safe zone for half pins may be further narrowed in distal femur fractures because, in addition to metaphyseal fracture extension, pins need to be placed more than a centimeter from the fracture to avoid potential pin track infection of fracture hematoma.¹⁷

One major limitation of our study warrants review. In comparison to the study by Riina et al,¹⁰ we did not dissect out the femoral artery or any of its branches. The majority of arteries branching off the femoral artery cross posterior to the femur, supplying the vastus lateralis as perforating vessels. Although these can be injured while drilling or with half pin overpenetration, their posterior location makes them less likely to be injured in comparison to nerve branches, which are always at risk along the anterior femur. Furthermore, although nerve injury may potentially lead to some segmental or possibly more extensive muscle weakness, injury to perforating femoral arteries is ultimately of little clinical long-term consequence given the robust and abundant collateral circulation about the femoral shaft. The concern for extensive muscle weakness is made more apparent when one considers that in our study, each nerve branch typically innervated more than 1 muscle belly of the quadriceps mechanism, in some instances innervating 3. Some cadaveric limbs also had as few as 2 major branches crossing anterior femur, indicating that an injury to just 1 branch could potentially lead to 50% loss of quadriceps activity (Table 1). In one specimen in this study, the first femoral nerve branch draped longitudinally over the anterior femur for a distance of 4.8 cm, indicating that potential clinical situations exist where serious neurologic injury can occur with anterior pin placement even if soft tissue protection is used. Persistent quadriceps weakness has recently been reported in patients with femoral shaft fractures after nailing and has been presumed to be due to neuromuscular insult from the fracture itself.^{18,19} Additive effects of further neurologic injury to the quadriceps muscle may prolong rehabilitation and recovery of strength and muscle endurance, with the potential for compromised long-term recovery of function.

In conclusion, the safe zone for anterior pin placement is as narrow as 12 cm in length and begins 7.5 cm above the proximal pole of the patella. In contrast, the entire lateral side of the femur is safe for placement of pins, including distally beyond the synovial reflection of the suprapatellar pouch. We recommend the use of alternative frame constructs with either anterolateral or lateral femoral pins given the limitations and risks of anterior pin placement.

REFERENCES

1. Pape HC, Hildebrand F, Pertschy S, et al. Changes in the management of femoral shaft fractures in polytrauma patients: from early total care to damage control orthopedic surgery. *J Trauma*. 2002;53:452–461.
2. Levy BA, Krych AJ, Shah JP, et al. Staged protocol for initial management of the dislocated knee. *Knee Surg Sports Traumatol Arthrosc*. 2010;18:1630–1637.
3. Egol KA, Tejwani NC, Capla EL, et al. Staged management of high-energy proximal tibia fractures (OTA Types 41). The results of a prospective, standardized protocol. *J Orthop Trauma*. 2005;19:448–455.
4. Berkson EM, Virkus WW. High-energy tibial plateau fractures. *J Am Acad Orthop Surg*. 2006;14:20–31.
5. Haidukewych GJ. Temporary external fixation for the management of complex intra- and periarticular fractures of the lower extremity. *J Orthop Trauma*. 2002;16:678–685.
6. Anglen JO, Aleto T. Temporary transarticular external fixation of the knee and ankle. *J Orthop Trauma*. 1998;12:431–434.
7. Maiocchi AB. *Atlas for the Insertion of Transosseous Wires and Half-Pins. Ilizarov Method*. 6th ed. Milan, Italy: Medi Surgical Video; 2007.
8. Behrens F, Searls K. External fixation of the tibia. Basic concepts and prospective evaluation. *J Bone Joint Surg Br*. 1986;68:246–254.
9. Stark E, Stucken C, Trainer G, et al. Compartment syndrome in Schatzker type VI plateau fractures and medial condylar fracture-dislocations treated with temporary external fixation. *J Orthop Trauma*. 2009;23:502–506.
10. Riina J, Tornetta III, Ritter C, et al. Neurologic and vascular structures at risk during anterior-posterior locking of retrograde femoral nails. *J Orthop Trauma*. 1998;12:379–381.
11. Collinge C, Kennedy J, Schmidt A. Temporizing external fixation of the lower extremity: a survey of the Orthopaedic Trauma Association membership. *Orthopedics*. 2010;33:239–244.
12. Clinical Trial # NCT00610701. Available at: www.clinicaltrials.gov. Accessed October 20, 2011.
13. Vining NC, Pasque CB. External fixation about the knee in high-energy war injuries. *Tech Knee Surg*. 2010;9:2–10.
14. Mercer D, Firoozbakhsh K, Prevost M, et al. Stiffness of knee-spanning external fixation systems for traumatic knee dislocations: a biomechanical study. *J Orthop Trauma*. 2010;24:692–696.
15. Behrens F. General theory and principles of external fixation. *Clin Orthop Relat Res*. 1989;241:15–23.
16. Behrens F, Johnson WD. Unilateral external fixation: methods to increase and reduce frame stiffness. *Clin Orthop Relat Res*. 1989;241:48–56.
17. Green S. Pin tract infection. In: Garland D, ed. *Complications of External Skeletal Fixation. Causes, Prevention, and Treatment*. Springfield, IL: Charles C. Thomas; 1981.
18. Helmy N, Jando VT, Lu T, et al. Muscle function and functional outcome following standard antegrade reamed intramedullary nailing of isolated femoral shaft fractures. *J Orthop Trauma*. 2008;22:10–15.
19. Ricci WM, Schwappach J, Tucker M, et al. Trochanteric versus piriformis entry portal for the treatment of femoral shaft fractures. *J Orthop Trauma*. 2006;20:663–667.