



^aDivision of Urology,
Department of Surgery, The
Hospital for Sick Children,
University of Toronto, 555
University Avenue, Toronto ON
M5G 1X8, Canada

^bInstitute of Urology, St. Luke's
Medical Center, Philippines.
279 E Rodriguez Sr. Avenue,
Quezon City, Metro Manila,
Philippines

^cSocial Work Department, The
Hospital for Sick Children,
University of Toronto, 555
University Avenue, Toronto, ON
M5G 1X8, Canada

* Correspondence to: Joao Luiz
Pippi Salle, Division of Urology,
The Hospital for Sick Children,
University of Toronto, 555
University Avenue, Toronto,
M5G 1X9, Canada. Tel.: +1
(437) 230-0602
kchuarivera@gmail.com
(K.C. Rivera)
pippi.salle@sickkids.ca, salle-pippi@gmail.com (J.L. Pippi
Salle)

Keywords

Exstrophy; Epispadias; Bladder
reconstruction; Complete pri-
mary repair of exstrophy;
Staged repair of exstrophy

Received 20 July 2025
Revised 30 November 2025
Accepted 12 December 2025
Available online 17 December
2025

Original Research

Update and mid-term follow up of classic bladder exstrophy managed by the Toronto approach (Modified staged repair): Continence status, sexual function and upper tract functional outcomes



Kay Chua Rivera ^{a,b}, Michael Erlano Chua ^{a,b}, Abby Varghese ^a,
Marilyn Wong ^a, Noreen Goraya ^c, Darius J. Bägli ^a, Mandy Rickard ^a,
Armando J. Lorenzo ^a, Rodrigo L.P. Romao ^a, Joao Luiz Pippi Salle ^{a,*}

Summary

Introduction

The modified staged repair, or Toronto approach to reconstruct classic bladder exstrophy, involves bladder neck (BN) tailoring and bilateral ureteral reimplantation during primary closure, and later epispadias repair using external corpora rotation and a rotational penile skin flap. It aims to incorporate the advantages of complete primary repair while minimizing risks of upper tract deterioration and penile ischemia and improve cosmetic appearance of the genitalia. We present long-term outcomes for our initial patient series.

Methods

All patients with initial operation between 2000 and 2014 were reviewed. Data on demographics, continence, erectile and ejaculatory function, cosmetic appearance of the genitalia, and upper tract status were collected.

Results

Twelve male and four female patients were identified, with median follow-up of 12.7 (IQR 10.9–15.4) and 12.5 years (IQR 10.6–15.6), respectively. Full continence (voiding with no leaks, dry periods ≥ 3 h) was achieved in two of 12 males and two of four females. Five of 12 males and all four females had dry periods longer than 1 h. Nine of 12 males and all females attained volitional voiding. Three of 12 males and one of four females underwent additional

continence procedures. None have undergone augmentation cystoplasty or bladder neck closure.

Of seven males with preliminary sexual function data, all experienced erections, straight in five, with recurrent dorsal curvature and ventral curvature in one patient each. Four of seven ejaculate and none have attempted penetrative intercourse. All seven males reported satisfactory cosmetic appearance despite a subjectively shorter penis.

Although transitory dilations of the ureters were seen immediately post op, none had scarring, hydronephrosis, or febrile urinary tract infections at latest follow-up. One patient had an eGFR on the upper range of CKD 2, while the rest of the cohort had eGFR ≥ 90 mL/min/1.73m². Mean bladder capacity on ultrasound was 145 mL for males and 97 mL for females.

Conclusion

The present data suggests that the modified staged repair of exstrophy (Toronto approach) is associated with acceptable continence outcomes while minimizing escalation to augmentation cystoplasty and bladder neck closure. Most patients void volitionally and stay dry for 1–3 h, but few are fully continent or able to remain dry for 3 h or more. No patients in the cohort had CKD3 or worse, and none had hydronephrosis or history of febrile urinary tract infections. Most males experience ejaculation and straight erections. There was no glanular or corporal tissue loss.

<https://doi.org/10.1016/j.jpuro.2025.105700>

1477-5131/© 2025 Journal of Pediatric Urology Company. Published by Elsevier Ltd. All rights are reserved, including those for text and data mining, AI training, and similar technologies.

Introduction

The optimal surgical approach to exstrophy-epispadias complex continues to be controversial. While variations exist, the complete primary repair of exstrophy (CPRE) typically involves closure of the bladder plate and abdominal wall, funneling of the bladder neck (BN), and simultaneous repair of epispadias in males. In contrast, the modern staged repair of exstrophy (MSRE) involves bladder closure as a first stage without BN repair, with later repair of epispadias. Our institution modified the staged repair, hypothesizing that continence outcomes would be comparable to CPRE, while upper tract deterioration would be minimized and penile cosmesis improved. Previously [1], we described our initial series of male patients who underwent primary closure of bladder plate with simultaneous BN funneling, reimplanting the ureters to protect the upper tract from the bladder pressure associated with increase of outlet resistance and presence of primary vesico-ureteral reflux. Also, epispadias was repaired later using external corpora rotation and rotational penile skin flaps. During the same period four girls underwent similar closure along with clitoroplasty and monsplasty. We now describe the mid-term outcomes of these patients.

Methods

All patients with the initial operation between 2000 and 2014 were reviewed [1]. These patients were seen and reviewed at least annually with history, physical exam, ultrasound of the upper tracts and bladder, and renal function laboratory tests. Continence and pad use data were recorded at each visit. To assess long-term outcomes for the present study, variables of interest included demographic information; continence and volitional voiding; indicators of upper tract status including hydronephrosis and estimated glomerular filtration rate (GFR); rates of urinary tract infections; and preliminary sexual function.

Patient-reported continence was defined following contemporary literature on exstrophy [2,3] as the ability to remain dry for 3 or more hours. Partial continence was defined as dryness for 1–3 h periods [4]; for these patients we also determined the median number of pads used per day. For those patients with partial or no continence, acceptability of the status quo and interest in further continence interventions were determined. Urinary tract infections (UTIs) were defined as the presence of lower urinary tract symptoms and pyuria and/or bacteriuria on urinalysis or positive urine culture. Febrile UTIs included UTIs with febrile episodes and other systemic symptoms. Recurrent UTIs were defined as two or more UTIs in 6 months, or 3 within 1 year. Chronic kidney disease (CKD) was staged using estimated glomerular filtration rate (eGFR) based on serum creatinine.

Hydronephrosis was graded according to the Society of Fetal Urology [5]. Scarring on ultrasound was defined as the loss of definition of capsular echo, irregularity of cortical outline, loss of pyramids, or proximity of sinus echoes to cortical surface [6]. Non-invasive determination of mean bladder capacity was done by passive [or natural] filling on

ultrasound or during uroflowmetry study, measuring voided volume and post-void residual.

Ethics approval included permission to inquire about sexual function in adolescents and written consent was obtained for photography and sexual function questionnaires. For males information was gathered on penile ischemia or atrophy, penile curvature, appearance, acceptability of appearance and urethral location, and erectile and (for Tanner stage 5 patients) ejaculatory function. Information on presence of erections, pain, and ejaculations was gathered using a standard clinic questionnaire. Penile curvature was assessed based on patient self-report and corroborated by pictures with an erect penis.

Descriptive statistics were employed to analyze the data. Microsoft Excel was used to summarize data and compute medians and interquartile ranges.

Surgical technique: bladder and abdominal closure

Patients included in the study underwent modified staged repair of exstrophy under general anesthetic with epidural catheter placement. Most operations were performed or supervised by the senior author. After dissection around the para-exstrophic mucosa, the bladder was freed from its attachments. When bladder plate size and characteristics were favorable, cephalotrigonal intravesical reimplantation was done [7] with 5Fr feeding tubes as ureteral catheters.

BN tailoring: the trigonal area was funneled all the way to the verumontanum, using bladder mucosa striations to guide the area for tailoring. Lateral to this demarcation, the mucosa was excised while the underlying detrusor muscle was left intact. BN was then tubularized proceeding cephalad from the verumontanum, using interrupted polydioxanone sutures. Wider edges of mucosa were left around the verumontanum to facilitate tubularization. Care was taken to preserve a caliber of 15–20 mm at the BN to avoid stenosis. The denuded detrusor was then used to reinforce the tubularized BN with the goal of increasing outlet resistance and decreasing fistula formation.

Urethral and suprapubic catheters were inserted, followed by completion of bladder wall closure with interrupted sutures. Bilateral inguinal hernia repair was then undertaken using the same incision in boys. (In girls, hernia repairs were performed only if symptomatic.) Bilateral oblique iliac wing osteotomies were then undertaken by our institution's orthopedic surgeons.

Approximation of the pubic bone was done with large polydioxanone figure-of-eight sutures, with internal rotation of the hips for good apposition. In male patients, care was taken to identify compromise of penile blood supply. Penile appearance and color were assessed, and in a few cases intraoperative Doppler ultrasound was used to verify good cavernosal arterial supply. Any doubt would prompt release of the pubic suture and re-approximation with less tension [8]. The procedure was completed with abdominal wall closure and umbilicoplasty. Postoperatively, the patients were immobilized with modified Bryant's traction [9] for 3–4 weeks. The suprapubic tube was maintained until effective voiding per urethra was documented.

Surgical technique: repair of epispadias

The epispadiac penis was repaired 6–9 months after recovery from the initial repair. Intramuscular testosterone (2 mg/kg) was administered 90, 60 and 30 days prior to surgery. The procedure began with cystourethroscopy, allowing assessment of the ureters, the location of the verumontanum, and the BN caliber. Complete penile corporal disassembly was performed following principles described by Mitchell-Bagli for CPRE technique [10]. Correction of dorsal curvature was done with external rotation and fixation of the corporal bodies using a double layer of interrupted stitches (non-absorbable dorsally and absorbable ventrally, juxtaposed to the neourethra). If the verumontanum was still high in the BN or inside the bladder, funneling of BN was repeated.

Intraoperatively the surgeon assessed the ability to place the urethral opening orthotopically or leaving the meatus at an hypospadiac location if necessary with plans of later repair. Skin closure was done using penile skin rotational flaps as we previously described [11]. Suprapubic and urethral catheters were left in place if the BN needed re-funnelling. Otherwise, an indwelling 8Fr silicone catheter was placed and removed 7–10 days post operatively. The reader may view all technical details through the following link: <https://www.dropbox.com/scl/fi/plnq9yau3uul7xtgq72y8/Staged-Repair-of-Exstrophy-10-23min-The-Toronto-Approach-with-audio.mp4?rlkey=f8d9tnlxl713diqxr1exvo5k4&dl=0>.

Surgical technique: Clitoroplasty and monsplasty

Girls underwent clitoroplasty and monsplasty at initial repair. Limited distal mobilization of the urogenital sinus using Y–V vaginoplasty was performed. Both hemi-clitoral bodies were re-approximated and a monsplasty was performed [12].

Results

Patient demographics

We identified twelve male patients who underwent the staged repair, and four females who underwent the above technique for closure of exstrophy. Among the male patients this includes eleven from the initial report from 2019 [1] and one operated immediately thereafter. Their demographic characteristics are described in Table 1. Outcomes were assessed at latest follow-up (median 12.7 years after initial bladder closure for both males and median 12.5 years for females).

Continence

Table 2 describes the patients' continence characteristics. Two of twelve male patients were fully continent, remaining dry for ≥ 3 h with no leaks [2,3]. One of these two male patients initially required intermittent catheterization via a Mitrofanoff channel but stopped due to being continent and volitionally voiding per urethra with low residuals. Five of 12 males had dry periods between 1 and 3 h. The median pads per day for the population with leaks was 2.5 and the median longest dry period was 2 h. Nine of 12 males attained volitional urethral voiding with production of a urine stream.

Two female patients were fully continent. None of the female patients were catheterizing. All females had dry periods >1 h, with a median of 2.5 pads used per day. All four females achieved volitional voiding via the urethra.

Three of 12 males and 1 of 4 females underwent additional procedures for continence. One male had dextranomer/hyaluronic acid copolymer bulking agent (Deflux®) injection to the bladder neck, while another male underwent a bladder neck reconstruction with Mitrofanoff catheterizable channel. The remaining male patient underwent creation of a Mitrofanoff channel alone. One female patient

Table 1 Characteristics of male and female patients on long-term follow-up post repair of exstrophy-epispadias.

	Male (N = 12)	Female (N = 4)
Median age at bladder closure (days)	2	2
Median age at repair of epispadias (males) (days)	376 (IQR 376–481)	N/A
Median length of follow-up from surgery (years)	12.7 (IQR 10.9–15.4)	12.5 (IQR 10.6–15.6)
Median age at latest follow-up (years)	13.4 (range 10.2–16.7)	12.6 (range 9.3–17.9)
BN funnelling and reimplantation undertaken	11	4

Table 2 Continence rates and dry periods in male and female patients' status post the modified staged repair of exstrophy.

	Male (N = 12)	Female (N = 4)
Full continence	2	2
On clean intermittent catheterization	1	0
Partial continence	5	2
Median pads per day	2.5 pads (N = 8)	2 (N = 4)
Range of pad use per day in the partially continent population	1 to 5	6 to 8
Volitional voiding per urethra with production of urine stream	9	4

underwent injection of dextranomer/hyaluronic acid to the bladder neck. None had surgical closure of the bladder neck. Two female patients developed bladder neck stenosis. One required a single urethral dilation, and the other, three dilations, after which continence was maintained. The surgeries performed after repair of exstrophy-epispadias have been summarized in [Table 3](#).

Urinary tract infections and upper tract status

Four of twelve males, and no females had a history of recurrent, nonfebrile UTI. Nonfebrile UTIs in four males were intermittent, not persistent, throughout follow-up. None required continuous antibiotic prophylaxis. No male or female had a history of febrile UTI, recurrent or otherwise. One continent female patient developed recurrent bladder stones in association with bladder neck stenosis; following repeated dilations and resolution of stenosis, no further stones occurred.

CKD was staged as stated in the methodology. Proteinuria was not consistently assessed, therefore CKD stage 1 cannot be excluded; however, all patients had eGFR \geq mL/min/1.73m² excluding stage 3 CKD or worse. The median eGFR in male patients was 103.5 (range 88–118) mL/min/1.73 m², with only one patient with eGFR <90 mL/min/1.73 m². The median eGFR in females was 111 (range 99–144) mL/min/1.73 m². Thus given the above criteria one patient was classified as being on the upper range of CKD 2, without a history of urinary tract infections, febrile or otherwise; of note, his renal size was at the 90th percentile for age ([Appendix Table 1](#)). Although transient ureteral dilation was seen on close follow-up post-operatively, on longitudinal follow-up, no patient had upper tract dilation on their most recent assessment. None had evidence of scarring on renal ultrasound, although one patient had a slight and diffuse increase in parenchymal echogenicity.

Table 3 Surgical procedures undertaken after repair of exstrophy-epispadias.

	Number of patients who underwent additional surgical procedures
Male	
Bulking injection to the bladder neck	1
Open reconstruction of bladder neck	1
Creation of Mitrofanoff appendicovesicostomy	2
Bladder neck dilation	1
Hypospadias repair	2
Correction of ventral chordee	1
Female	
Bulking injection to the bladder neck	1
Urethral dilation	2
Cystoscopic removal of bladder stone	1

[Appendix Table 1](#) describes renal sizes on most recent follow-up and compares these renal sizes to normative values described by age and sex from a previous study [13]. When two values were available the lower renal size was used. Renal sizes by age were variable, with 10 of 16 patients at or above the 50th percentile, and 5 patients at 25th percentile and below. One patient (ID #5) did not have ultrasound data proximate to the most recent follow-up and was excluded from analysis. Two patients (ID #11 and #12) had congenital solitary kidneys.

Given the absence of febrile UTIs and hydronephrosis, the patients were not subjected to routine voiding cystourethrogram on follow-up, and thus evidence of reflux was not documented. Maximal bladder capacity was measured as described, with a mean of 145 mL (ranging from 58 mL to 200 mL) in males, and 97 mL (ranging from 27 mL to 203 mL) for females.

To date none of the patients is willing to have further procedures, including augmentation cystoplasty and catheterizable channels to improve continence.

Preliminary sexual function and penile appearance

[Table 4](#) provides data on the seven male participants consenting and able to provide information on erectile function. Seven reported the ability to have erections. None reported associated pain. Five had straight erections, one had recurrent dorsal chordee, and one had ventral curvature. The latter was confirmed clinically by patient report and intraoperatively with artificial erection. The curvature was attributed to a short urethra relative to corporal growth, and this was corrected surgically, with the meatus orthotopic and the erection straight on latest follow-up ([Fig. 1](#)). Six patients, who were all sexual maturity Tanner stage 5, consented to provide data on ejaculation. Four of these patients reported the ability to have successful ejaculation, one reported that he had erections but no ejaculation, and one reported that he had not yet tried to ejaculate. Detailed qualitative parameters such as force of emission or amount of ejaculate could not be reliably captured in this adolescent cohort.

Six of seven patients were satisfied with their penile appearance and opted for no further interventions for

Table 4 Erection and ejaculation data in male participants after modified staged repair of exstrophy.

	Male patients
Able to have erections (N = 7)	7
Pain on erections (N = 7)	0
Curvature of erections (N = 7)	
• Straight	5
• Dorsal curvature	1
• Ventral curvature	1
Ejaculate (N = 6)	
• Not yet attempted	1
• Present	4
• Absent	1
Penetrative intercourse (N = 6)	
• Successful	0
• Not yet attempted	6

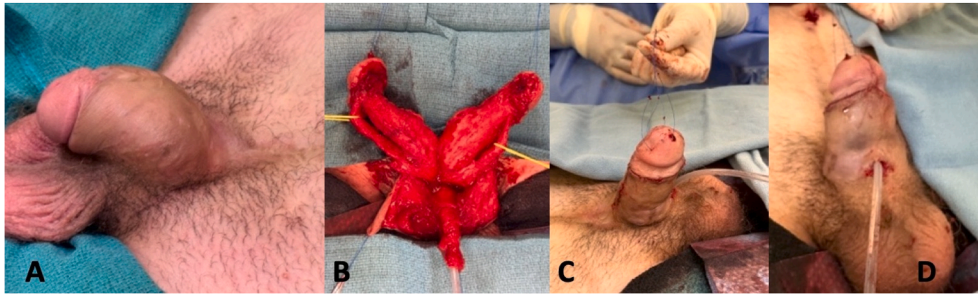


Fig. 1 Ventral penile curvature after epispadias repair, corrected with total penile disassembly and caverno-cavernostomy. *A* - Penile appearance prior to correction. *B* - total penile disassembly. *C* - post correction of ventral curvature. *D* - hypospadiac meatus after correction of ventral curvature.

cosmesis or curvature correction. One had recent chordee correction as mentioned, and was satisfied with his penile appearance thereafter. Thus seven of seven males reported satisfactory cosmetic appearance despite subjectively perceiving a somewhat short penis; penile length was not formally measured, but representative photographs are provided. Fig. 2 shows images, obtained with consent, of the long-term postoperative appearance of these patients.

Table 5 describes urethral orifice locations in males. Eight out of 12 had a urethral orifice in a glanular or orthotopic location, one was coronal, and one was sub-coronal. One patient, whose orifice had been hypospadiac after epispadias repair, had two failed repairs, and continues to have an orifice in a penoscrotal location. Another patient remained with a proximal hypospadias after epispadias repair and has been reluctant to undergo further surgery to advance the orifice.

Discussion

The data suggests that the Toronto modification of staged repair is associated with urethral voiding in most patients, with at least partial continence in most cases, normal upper tracts with no febrile UTIs, and acceptable preliminary markers of sexual function. This represents a positive step in the management of exstrophy-epispadias complex, as we continuously search for better outcomes in terms of cosmesis, sexual function, continence, bladder capacity, upper tract function, and quality of life.

Primary bladder plate closure, without addressing the BN, followed by epispadias repair at 1–2 years of age and continence procedures around age 7, was proposed in the initial development of staged repairs. Later, the same group made modifications to the original technique and described the MSRE [14,15]. Of note, these changes did not include creating outlet resistance or performing ureteral reimplantation at primary closure. This had the disadvantage of developing smaller bladder capacity when compared to CPRE [16,17].

In 1994, Bagli and Mitchell described the CPRE as primary bladder closure and epispadias repair using internal corpora rotation, completing penile skin closure with reverse Byars flaps. This procedure appears to generate better outlet resistance, leading to increased bladder capacity when compared to MSRE [16,17]. Nevertheless, it has the disadvantage of potential penile ischemia [18].

Recently Joshi et al. modified the CPRE, adding ureteral reimplantation as well as corporal external rotation for epispadias repair as described by Baka-Ostrowski and our group [8,19]. Another technique, the Kelly repair, involves radical soft tissue mobilization and epispadias repair as single or staged procedures [20–22].

While each approach has its own advantages and disadvantages, the modified staged repair or the Toronto approach endeavors to incorporate the advantages of CPRE, namely increase in bladder capacity, while minimizing the risks of upper urinary tract deterioration and penile ischemia. Early in our experience we started performing ureteral reimplants during primary bladder closure and simultaneous epispadias repair CPRE-BUR, observing less hydronephrosis secondary to VUR as well as less UTIs [7]. The next step was staging the repair to minimize risk of penile tissue ischemia, performing epispadias repair around age one with the use of preoperative testosterone stimulation which made the procedure safer. We also incorporated the concept of external corpora rotation for repair of dorsal curvature and skin closure using rotational penile skin flaps to achieve better cosmesis in boys undergoing epispadias repair [11]. In girls, improved cosmesis was achieved performing a simplified monsplasty as per our previous description [12].

Continence, capacity, and risks to the upper tract

Continence definitions vary widely throughout exstrophy literature. We used the most commonly employed definition, namely the ability to be dry with voiding or catheterization every 3 h [2]. We also noted the ability to remain dry for more than an hour, defining those patients who were incontinent but not continuously leaking; Shaw and colleagues describe this as partial continence [4]. In our initial report, we hypothesized that BN tailoring at the initial bladder closure would provide outlet resistance that could result in increased bladder capacity and early bladder cycling. Care to avoid overtightening while creating outlet resistance is paramount. Two of our female patients had bladder neck stenosis, which were improved after recurrent bladder neck dilations.

Previous authors have favored performing epispadias repair at an earlier age, with the assumption that increasing outlet resistance improves bladder cycling and thus capacity over time [23]. This is an advantage of the CPRE, which

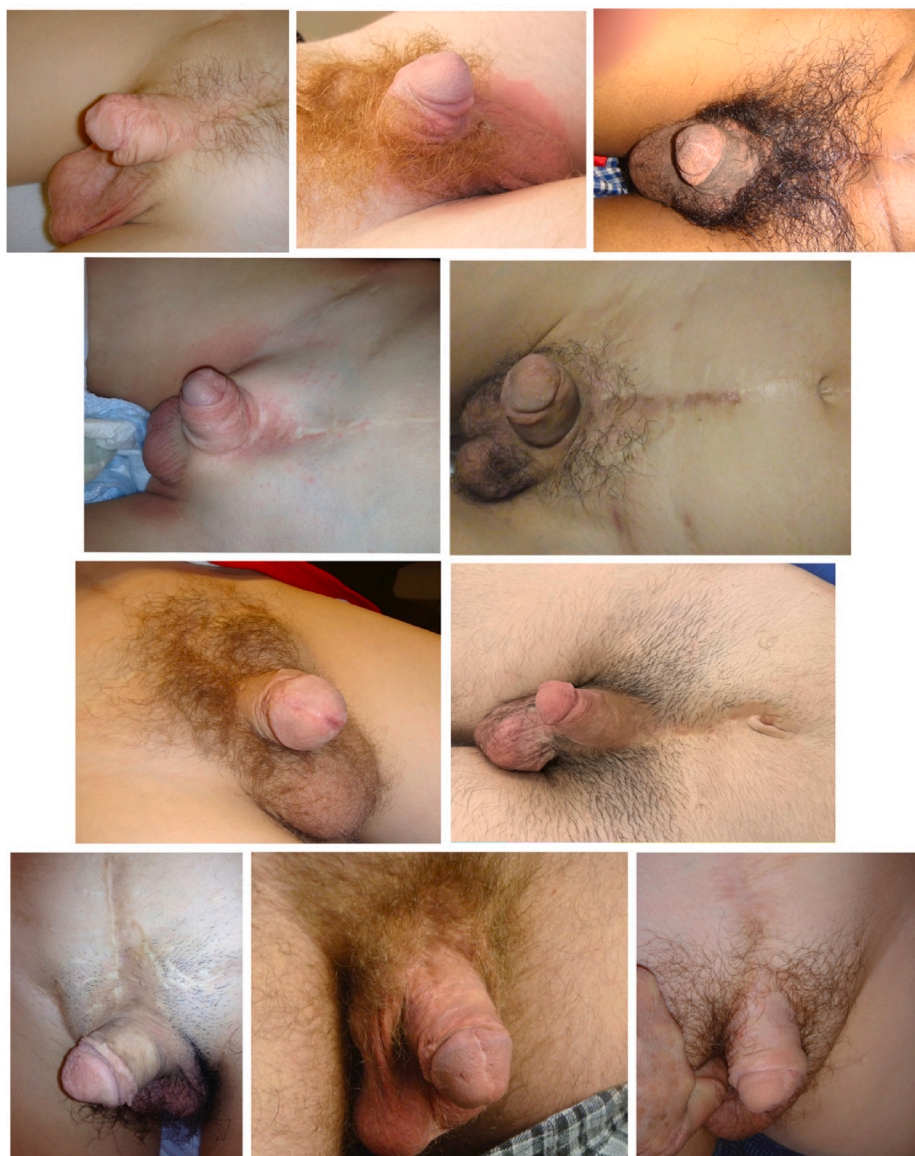

Fig. 2 Late follow up of some patients who underwent repair of exstrophy-epispadias with the Toronto Approach. Most patients were satisfied with the penile appearance.

however has known risks of penile ischemia and loss of penile tissue [1,18]. As such, the current approach is a modification of these earlier approaches; epispadias repair is delayed, minimizing risks of penile loss, and outlet resistance is created at the first stage to mitigate the risks of poor bladder growth and capacity. Moreover, bilateral ureteral

reimplantation, whenever possible, is done to decrease risk of upper tract deterioration and febrile UTIs following increase of outlet resistance [7,24].

While the current cohort continues to demonstrate suboptimal bladder capacities for age, our approach to repair of exstrophy results in reasonable continence rates for females, and somewhat less for males. This is consistent with previous reports achieving higher continence in females versus males [25]. It is noteworthy that so far none of the patients have undergone a bladder neck closure or augmentation cystoplasty. Acceptability of continence was determined by patient-reported satisfaction, and we noted that the members of the cohort who were volitionally voiding but not fully continent described contentment with their current continence. As mentioned under the Results section, to date none of the patients is willing to have further procedures, including augmentation cystoplasty and catheterizable channels to improve continence.

Table 5 Location of urethral orifice in male patients after epispadias repair.

Location of urethral orifice	Male patients (N = 12)
Orthotopic	5
Glanular	3
Coronal	1
Subcoronal	1
Penoscrotal	2

However, this situation may change in this cohort of sexually inexperienced adolescents whose continence expectations may evolve, particularly in the context of intimate relationships. Long-term follow-up of these patients should be informative.

The heterogeneity of techniques and definitions makes it difficult to establish a standard for continence rates. Previous studies have described rates of full dryness as high as 90–94% [3,4] but with as many as 70% of patients requiring augmentation cystoplasty [4] or 93% needing bladder neck closure [3]. The present study shows an improvement on volitional urethral voiding in comparison to previous studies, which have reported rates around 25% [3]. In many reports, volitional voiding is reported as part of the definition of continence along with 3-h dry periods [26,27], which results in widely disparate results and makes it difficult to establish an established comparator for urethral voiding only.

The current range of bladder capacity in males was 58–200 mL, in comparison to our range of 55–125 mL as described in our initial series [1], thus capacities were stable or modestly increased, with a higher proportion of patients now demonstrating volitional voiding and partial continence. The range of capacities in our female cohort was comparable or lower, from 27 to 203 mL. These capacities continue to be suboptimal compared to the non-exstrophy population for whom the 50th percentile bladder capacity is 365 mL [28].

Other authors have described the fine balance that is creation of outlet resistance *vis à vis* risks to the upper tract. In the current cohort, the lack of febrile UTIs, hydronephrosis, and obvious renal scarring on sonography reflect positively on the combination of bladder neck tailoring and bilateral ureteral reimplantation.

Renal function was estimated using serum creatinine at latest follow-up. Not all patients could be followed with DMSA scintigraphy, which is ideal to investigate renal function and detect renal scarring after pyelonephritis [29]. Previous authors have described a positive correlation of small (<5th percentile) renal size and DMSA alterations that may reflect post pyelonephritic scarring [30]. Comparison with normative values was undertaken because longitudinal ultrasound data were incomplete for all patients; however, in those with serial measurements, renal percentile ranking was generally maintained over time. In this cohort most patients maintained renal sizes higher than 50th percentile, while a small number was below 25th; of note, one patient had a kidney size lower than 5th percentile despite the absence of febrile UTIs post repair. While the present study reflects a positive development in balancing the benefits of outlet resistance versus the safety of the upper tracts, it also underlines the need for close follow-up after exstrophy repair, ideally with DMSA scintigraphy or other surrogates for renal function.

Penile loss, ischemia, and sexual function outcomes

Penile glanular or corporal loss has been reported after repair of exstrophy-epispadias, even in expert centers [1,27]. Proposed mechanisms of injury include a congenitally abnormal penile blood supply; compression of the blood supply when apposing the pubic diastasis; and direct

injury to the blood supply when mobilizing soft tissue. As we previously pointed out, compartment syndrome occurs when apposing the pubic bones [8]. This catastrophic consequence of repair, which for some time was likely underreported, led in part to our adoption of the current staged approach. The hypothesis was that delaying the repair of epispadias could minimize the possibility of penile vascular compromise, reducing risk of penile loss and resulting in more satisfactory cosmesis and sexual function. The data suggests the viability of the Toronto approach in preserving the ability to have straight, nonpainful erections with successful ejaculation in most patients. Whether this cohort of patients will be able to have penetrative intercourse is a topic for future investigation.

Limitations

The data has several limitations apart from the small number of patients in the initial series. Bladder capacity measurements were non-invasive and not corroborated by voiding diaries, which is a limitation of the study. Moreover, while nuclear scintigraphy provides more accurate data on renal scarring, not all patients were tested. Data on sexual function among males was limited by age at most recent follow-up, as some patients had not yet attempted to ejaculate, and no patient had attempted penetrative intercourse. Therefore, longer follow up is warranted to evaluate sexual function in this patient population. Moreover, we did not systematically assess genital perception or sexual function in females, which represents a limitation of this study. In addition, this is a single center study without an ability to perform a direct comparison. Outcomes may not be generalizable in the hands of other surgeons. We have done our best to describe the performed operations in great detail should other centers in future opt for the Toronto approach, potentially providing larger patient cohorts for comparison. Despite these limitations, our study provides useful information for the management of this complex patient population.

Conclusion

The modified staged repair of exstrophy (Toronto approach) achieves acceptable continence outcomes, with most patients in this series achieving at least partial continence and most voiding volitionally per urethra with a stream. To date, none underwent augmentation cystoplasty or bladder neck closure, although such intervention may be required in the future. Most patients of both sexes have volitional voiding and the ability to stay dry for 1–3 h, but fewer are fully continent. No patients had CKD stage 3 or worse, and none had hydronephrosis or febrile UTIs. Renal sizes by age were variable but most patients had longitudinal kidney sizes at the 50th percentile for age or higher. Most males had straight erections and ejaculation was present in the more mature males. Finally, there was no penile glanular or corporal loss.

Ethical approval

Approval from the institutional Research Ethics Board was obtained as in the original series.

Funding sources

The authors have no funding sources to declare.

Conflicts of interest

The authors have no financial or personal relationships with persons or organizations that may inappropriately influence this work.

References

- [1] Chua ME, Ming JM, Fernandez N, Varghese A, Farhat WA, Bagli DJ, et al. Modified staged repair of bladder exstrophy: a strategy to prevent penile ischemia while maintaining advantage of the complete primary repair of bladder exstrophy. *J Pediatr Urol* 2019 Feb 1;15(1):63-e1.
- [2] Lloyd JC, Spano SM, Ross SS, Wiener JS, Routh JC. How dry is dry? A review of definitions of continence in the contemporary exstrophy/epispadias literature. *J Urol* 2012 Nov;188(5):1900–4.
- [3] Maruf M, Manyevitch R, Michaud J, Jayman J, Kasprenski M, Zaman MH, et al. Urinary continence outcomes in classic bladder exstrophy: a long-term perspective. *J Urol* 2020 Jan;203(1):200–5.
- [4] Shaw MB, Rink RC, Kaefer M, Cain MP, Casale AJ. Continence and classic bladder exstrophy treated with staged repair. *J Urol* 2004 Oct 1;172(4):1450–3.
- [5] Kim SY, Kim MJ, Yoon CS, Lee MS, Han KH, Lee MJ. Comparison of the reliability of two hydronephrosis grading systems: the society for Foetal urology grading system vs. the onen grading system. *Clin Radiol* 2013 Sep 1;68(9):e484. Barry BP, Hall N, Cornford E, Broderick NJ, Somers JM, Rose DH. Improved ultrasound detection of renal scarring in children following urinary tract infection. *Clinical radiology* 1998 Oct 1;53(10):747–751.
- [6] Barry BP, Hall N, Cornford E, Broderick NJ, Somers JM, Rose DH. Improved ultrasound detection of renal scarring in children following urinary tract infection. *Clin Radiol* 1998 Oct 1;53(10):747–51.
- [7] Braga LH, Lorenzo AJ, Jreaz R, Bagli DJ, Salle JPL. Bilateral ureteral reimplantation at primary bladder exstrophy closure. *J Urol* 2010 Jun 1;183(6):2337–41.
- [8] Joshi RS, Shrivastava D, Grady R, Kundu A, Ramji J, Reddy PP, et al. A model for sustained collaboration to address the unmet global burden of bladder exstrophy-epispadias complex and penopubic epispadias: the international bladder exstrophy consortium. *JAMA Surg* 2018 Jul 1;153(7):618–24.
- [9] Meldrum KK, Baird AD, Gearhart JP. Pelvic and extremity immobilization after bladder exstrophy closure: complications and impact on success. *Urology* 2003 Dec 1;62(6):1109–13.
- [10] Mitchell ME, Bagli DJ. Complete penile disassembly for epispadias repair: the mitchell technique. *J Urol* 1996 Jan;155(1):300–4.
- [11] Pippi Salle JL, Jednak R, Capolicchio JP, França IM, Labbie A, Gosalbez R. A ventral rotational skin flap to improve cosmesis and avoid chordee recurrence in epispadias repair. *BJU Int* 2002 Dec;90(9):918–23.
- [12] Cook AJ, Farhat WA, Cartwright LM, Khoury AE, Salle JL. Simplified mons plasty: a new technique to improve cosmesis in females with the exstrophy-epispadias complex. *J Urol* 2005 Jun 1;173(6):2117–20.
- [13] Obrycki Ł, Sarnecki J, Lichosik M, Sopińska M, Placzyńska M, Stańczyk M, et al. Kidney length normative values in children aged 0–19 years—a multicenter study. *Pediatr Nephrol* 2022 May;1:1. 1.
- [14] Jeffs RD, Guice SL, Oesch I. The factors in successful exstrophy closure. *J Urol* 1982 May 1;127(5):974–6.
- [15] Stec AA, Baradaran N, Schaeffer A, Gearhart JP, Matthews RI. The modern staged repair of classic bladder exstrophy: a detailed postoperative management strategy for primary bladder closure. *J Pediatr Urol* 2012 Oct 1;8(5):549–55.
- [16] Gargollo PC, Borer JG, Diamond DA, Hendren WH, Rosoklija I, Grant R, et al. Prospective followup in patients after complete primary repair of bladder exstrophy. *J Urol* 2008 Oct;180(4S):1665–70.
- [17] Shnorhavorian M, Grady RW, Andersen A, Joyner BD, Mitchell ME. Long-term followup of complete primary repair of exstrophy: the Seattle experience. *J Urol* 2008 Oct;180(4S):1615–20.
- [18] Cervellione RM, Husmann DA, Bivalacqua TJ, Sponseller PD, Gearhart JP. Penile ischemic injury in the exstrophy/epispadias spectrum: new insights and possible mechanisms. *J Pediatr Urol* 2010 Oct 1;6(5):450–6.
- [19] Baka-Jakubiak M. Combined bladder neck, urethral and penile reconstruction in boys with the exstrophy-epispadias complex. *BJU Int* 2000 Sep;86(4):513–8.
- [20] Kelly JH. Vesical exstrophy: repair using radical mobilisation of soft tissues. *Pediatr Surg Int* 1995 Jul;10:298–304.
- [21] Leclair MD, Villemagne T, Faraj S, Suply E. The radical soft-tissue mobilization (Kelly repair) for bladder exstrophy. *J Pediatr Urol* 2015 Dec 1;11(6):364–5.
- [22] Leclair MD, Faraj S, Sultan S, Audry G, Heloury Y, Kelly JH, et al. One-stage combined delayed bladder closure with Kelly radical soft-tissue mobilization in bladder exstrophy: preliminary results. *J Pediatr Urol* 2018;14(6):558–64.
- [23] Kufner M, Gearhart JP, Mathews R. Impact of epispadias repair on bladder growth in boys with classic bladder exstrophy. *J Pediatr Urol* 2010 Dec 1;6(6):578–81.
- [24] Ramji J, Weiss DA, Romao RL, Eftekhazadeh S, Shah J, Frazier JR, et al. Impact of bilateral ureteral reimplantation at the time of complete primary repair of bladder exstrophy on reflux rates, renogram abnormalities and bladder capacity. *J Pediatr Urol* 2021 Jun 1;17(3):393-e1.
- [25] Capolicchio G, McLorie GA, Farhat W, Merguerian PA, Bägli DJ, Khoury AE. A population based analysis of continence outcomes and bladder exstrophy. *J Urol* 2001 Jun;165(6 Part 2):2418–21.
- [26] Husmann DA. Surgery insight: advantages and pitfalls of surgical techniques for the correction of bladder exstrophy. *Nat Clin Pract Urol* 2006 Feb 1;3(2):95–100.
- [27] Ellison JS, Shnorhavorian M, Willihnganz-Lawson K, Grady R, Merguerian PA. A critical appraisal of continence in bladder exstrophy: long-term outcomes of the complete primary repair. *J Pediatr Urol* 2016 Aug 1;12(4):205-e1.
- [28] Kaefer M, Zurakowski D, Bauer SB, Retik AB, Peters CA, Atala A, et al. Estimating normal bladder capacity in children. *J Urol* 1997 Dec;158(6):2261–4.
- [29] Moorthy I, Wheat D, Gordon I. Ultrasonography in the evaluation of renal scarring using DMSA scan as the gold standard. *Pediatr Nephrol* 2004 Feb;19:153–6.
- [30] Peratoner L, Pennesi M, Bordugo A, Melega R, Sorce P, Travan L, et al. Kidney length and scarring in children with urinary tract infection: importance of ultrasound scans. *Abdom Imaging* 2005 Dec;30:780–5.

Appendix Table

Appendix Table 1 Longitudinal renal measurements of patients on most recent follow-up.

Patient ID (N = 16)	Sex	Renal length R kidney (cm)	Renal length L kidney	Kidney length percentile by age ^a
1	M	11.4	11.7	90th
2	M	8.79	9.39	50th
3	M	9.93	8.7	25th
4	M	12.4	12	90th
5	M	Absent	Absent	N/A
6	M	9.7	9.6	50th
7	M	10.2	11	75th
8	M	10.3	10.8	75th
9	M	11.3	10	25th
10	M	7.71	7.91	25th
11	M	11.6	Absent	97.5th
12	M	8.24	8.1	25th
13	F	11.3	9.8	50th
14	F	Absent	12.7	97.5th
15	F	11.7	11	50th
16	F	10.2	8.4	2.5th

M, male; F, female.

^a Normative kidney lengths were based on Obrycki et al. [13].